

FATAL MYCOTIC DERMATITIS IN CAPTIVE BROWN TREE SNAKES (*BOIGA IRREGULARIS*)

Donald K. Nichols, D.V.M., Robbin S. Weyant, Ph.D., Elaine W. Lamirande, B.S.,
Lynne Sigler, M.Sc., and Robert T. Mason, Ph.D.

Abstract: Cutaneous fungal infections occurred in four captive brown tree snakes (*Boiga irregularis*). The ventral scales were most commonly affected, and lesions began as areas of erythema and edema with vesicle formation, followed by development of caseous brown plaques. Lesions usually started where ventral scales overlapped and spread rapidly. All snakes died within 14 days after clinical signs were first noted. The deaths of three of the snakes were directly attributable to the cutaneous disease; the other snake died from renal failure and visceral gout, most likely induced by gentamicin therapy. Histologically, lesions consisted of epidermal hyperplasia and hyperkeratosis, with foci of epidermal necrosis, intraepidermal vesicle formation, and subacute inflammation of the underlying dermis. These lesions were associated with bacteria and numerous septate, branched fungal hyphae within the epidermis and overlying serocellular crusts. Hyphae that penetrated through the superficial surface of the epidermis often formed terminal arthroconidia. The same species of fungus was isolated in pure culture from the skin of three snakes, but fungal cultures were not performed on samples from the fourth snake. The fungus has been identified as the *Chryso sporium* anamorph of *Nannizziopsis vriesii* based on its formation of solitary dermatophytelike aleurioconidia and alternate and fission arthroconidia. The source of the fungus in this outbreak was not determined; however, the warm, moist conditions under which the snakes were housed likely predisposed them to opportunistic cutaneous fungal infections.

Key words: Brown tree snake, *Boiga irregularis*, dermatitis, fungus, *Chryso sporium*, *Nannizziopsis vriesii*.

INTRODUCTION

Superficial fungal infections of the skin have been reported in a wide variety of captive reptiles.^{4-11,14,18,20,21,24,26-28} Snakes appear to be especially susceptible, and in most cases, the infections are considered secondary to poor husbandry and/or debilitation from other diseases.^{4,6,8,10,14,18} Several different fungi have been isolated from snakes with cutaneous mycoses, including species in the genera *Aspergillus*, *Candida*, *Chrysonila* (*Monilia*), *Fusarium*, *Geotrichum*, *Oospora*, *Penicillium*, *Trichoderma*, *Trichophyton*, and *Trichosporon*.^{4,7,8,10,14,18,20,21,24} However, the significance of their isolation is often difficult to evaluate because several of these fungi (e.g., *Fusarium*) are rapidly growing organisms that are common in the environment and could colonize damaged skin or overgrow other fungi in primary isolation.

From the Laboratory Sciences Section, Veterinary Resources Program (Nichols, Weyant, Lamirande), and the Laboratory of Biophysical Chemistry, National Heart, Lung and Blood Institute (Mason), National Institutes of Health, Bethesda, Maryland 20892, USA; and the University of Alberta Microfungus Collection, Devonian Botanic Garden, Edmonton, Alberta T6G 2E1, Canada (Sigler). Present addresses: Department of Pathology, National Zoological Park, Washington, D.C. 20008, USA (Nichols, Lamirande); The National Center for Infectious Diseases, Centers for Disease Control and Prevention, Atlanta, Georgia 30333, USA (Weyant); and the Department of Zoology, Oregon State University, Corvallis, Oregon 97331, USA (Mason).

Cutaneous infections caused by true dermatophytes are rare in snakes and other reptiles.^{4,8,21} In one report, *Trichophyton mentagrophytes* was identified as the cause of dermal lesions in a ball python.⁸ Others have identified soil-associated species including *T. terrestre* from normal scales of a boa constrictor (*Boa constrictor*)⁴ and *Chryso sporium* species from nodular subcutaneous lesions in a corn snake (*Elaphe gutatta gutatta*).^{3,4,13} The *Chryso sporium* anamorph of *Nannizziopsis vriesii*² Currah was recently identified as the cause of cutaneous mycosis in three species of chameleons.²¹ Here, we describe an outbreak of fatal mycotic dermatitis in a colony of captive brown tree snakes (*Boiga irregularis*) caused by this same fungal species.

CASE REPORT

In 1989, a colony of 12 (two male, 10 female) adult brown tree snakes was established at the National Institutes of Health (NIH) as part of a research project to study the cutaneous lipids of this species and their relation to brown tree snake reproductive behavior. These snakes had been collected from the wild on the island of Guam and transported to NIH. The snakes were housed singly or in pairs in specially designed Plexiglas cages.¹⁶ The bottoms of the cages were lined with paper towels, which were changed weekly. Small tree branches collected from several species of trees growing around NIH were placed within the cages to afford climbing opportunities for the snakes. Glass water bowls and hiding boxes made from

plastic drawer liners (Rubbermaid, Wooster, Ohio 44691, USA) were also provided. Water was changed in the water bowls every 2–3 days. Cages and all their contents were completely cleaned and disinfected every 4 wk using hot water and an iodinated cleanser (Betadine 10%, Purdue Frederick Co., Norwalk, Connecticut 06850, USA).

Because brown tree snakes are a tropical species, room air flow was intentionally limited (<10 room air exchanges/hr) to help maintain conditions of relatively high temperature and humidity. Room temperature was maintained at 25–30°C and room humidity was kept at 75–80%. The interior of each cage was also sprayed once or twice daily with a fine mist of water to further increase the relative humidity.

Snakes were offered a meal of freshly killed laboratory mice every 2 wk, and the snakes appeared to remain healthy for the first 11 mo in captivity. Once every 2–3 mo during this time, the snakes were anesthetized with methohexital (Brevital, Eli Lilly and Co., Indianapolis, Indiana 46285, USA; 10 mg/kg s.c.), and the outer layers of skin lipids from each snake were extracted into liquid hexane and later analyzed using gas chromatography/mass spectrometry to assay for the presence of cutaneous sex pheromones. Lipid extractions were performed using procedures as previously described.^{15,17,22,23} The head and cloacal region of each snake were held out of the liquid, and the midbody was swirled through the hexane for approximately 10 sec; the snakes were then dried off with a paper towel and returned to their cages.

Over an approximately 4-wk period in February–March 1990, four brown tree snakes were affected with a rapidly progressing cutaneous mycosis. The first two affected snakes (1 and 2) were housed together. Snakes 3 and 4 were housed singly in cages that were not directly adjacent to each other or to that of snakes 1 and 2. The locations of the three cages in which the affected snakes were housed appeared to be random within the snake colony room.

Clinical signs in all snakes began with focal to multifocal erythema and edema of the ventral scales, often accompanied by the formation of cutaneous vesicles filled with clear to cloudy serous fluid. Vesicles ruptured and/or were replaced by raised brown caseous plaques. This caseous material could be peeled from the skin with the superficial layers of keratin; the underlying epidermis often was dry and necrotic. Scattered foci of dermal hemorrhage were also present. Lesions usually began where ventral scales overlapped and then spread rapidly, affecting up to 50% of a snake's ventral surface. Skin lesions in snake 2 were de-

tected 3 days after they were first noted in snake 1. Cutaneous lesions in snake 3 were initially seen 6 days after snakes 1 and 2 had died. The lesions in snake 4 were detected the day after snake 3 was found dead.

Lesions in snakes 1 and 2 were treated daily with topical applications of povidone–iodine ointment (Prodine Ointment, Phoenix Pharmaceutical, St. Joseph, Missouri 64506, USA). Because the lesions were initially suspected to be caused by bacterial infections, these snakes also were given 2.5 mg/kg i.m. of gentamicin sulfate (Gentocin, Schering-Plough Animal Health, Kenilworth, New Jersey 07033, USA); the antibiotic treatment was repeated 5 days later. Snake 3 was also treated daily with topical povidone–iodine ointment but was not given gentamicin. The fourth snake was not treated.

All affected snakes died 3–14 days after the onset of clinical signs, and a complete necropsy was performed on each animal. Gross lesions in the skin of each snake consisted primarily of the previously described raised brown caseous plaques on and between the ventral scales (Fig. 1) with erythema, hemorrhage, and/or necrosis of the underlying tissues. In some of these foci, fine white granular to powdery material was present along the surface of the plaques between scales (Fig. 1). Snake 1 also had swollen, pale tan kidneys and moderate amounts of chalky white material covering the epicardium and internal surface of the pericardium; similar white material was present within the subcutis and was scattered over the serosal surfaces of most coelomic organs. Several firm, yellow-brown, degenerate follicles were present in the ovaries of snake 2. Internal organs of snakes 3 and 4 were grossly unremarkable.

Postmortem specimens of skin and other organs were collected for bacterial and/or fungal cultures. Representative samples of all major organs were fixed in 10% buffered formalin and processed routinely for histopathologic evaluation.

Aerobic and anaerobic bacterial cultures of the lung, peritoneum, and stomach from snake 1, lung and ovary from snake 2, and heart blood from snake 3 were negative; cultures of liver from snake 4 grew *Pseudomonas aeruginosa*. Bacterial cultures of the skin grew a *Clostridium* sp. and a *Flavobacterium* sp. from snake 1, *Enterobacter cloacae*, *Escherichia coli*, and an alpha-hemolytic species of *Streptococcus* from snake 3, and *P. aeruginosa* from snake 4.

Samples of skin from snakes 1, 3, and 4 inoculated onto inhibitory mold agar (Remel, Lenexa, Kansas 66215, USA) for routine fungal culture yielded pure cultures of the same filamentous mold

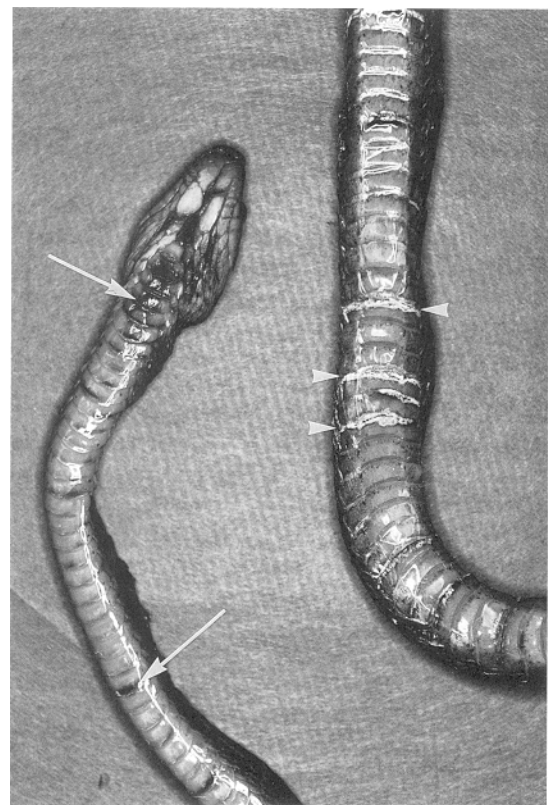


Figure 1. Brown tree snake (*Boiga irregularis*) with cutaneous mycosis. Snake is in dorsal recumbency. Note dark plaques along ventral surface of the head and between ventral scales (arrows). Granular white material is also present between some scales (arrowheads).

provisionally identified as a species of *Trichosporon* or *Geotrichum* because of its development of arthroconidia. A subculture of one isolate was submitted to the University of Alberta Microfungus Collection and Herbarium (UAMH, deposited as UAMH 6642). Based on similar growth characteristics and morphology, the snake isolate was recognized as belonging to a group of fungi previously isolated from skin lesions in lizards and other snake species for which the name *Chrysosporium* anamorph of *N. vriesii* has been used.²¹ The brown tree snake isolate was compared with other isolates by growing them on several different media under a variety of conditions commonly used for the identification of dermatophytes and similar fungi.^{12,21} Colonies of the isolate (Fig. 2) on Sabouraud glucose agar (Difco Laboratories, Detroit, Michigan 48232-7058, USA) and Mycosel agars containing cycloheximide at 400 $\mu\text{g/ml}$ (Becton Dickinson Microbiology Systems, Cockeysville, Maryland 21030, USA) were moderately fast growing (3.5–4

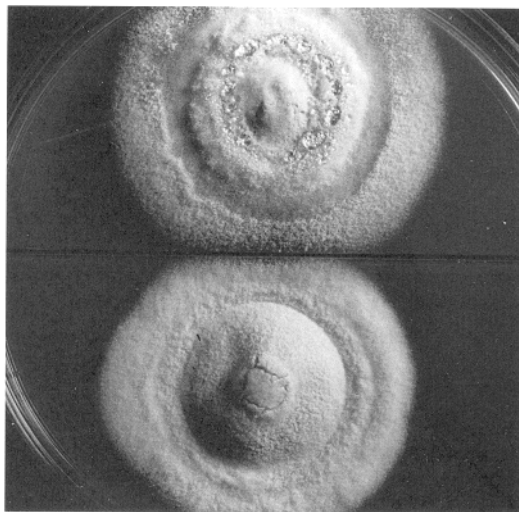


Figure 2. Colonies of *Chrysosporium* anamorph of *Nannizziopsis vriesii* (UAMH 6642) after 35 days at 25°C. Top: Sabouraud glucose agar; bottom: mycosel agar.

cm in 5 wk at 25°C), yellowish white to pale yellow, velvety to powdery, and slightly zonate. In slide culture preparations,¹² solitary conidia (aleurioconidia) 4–6 μm long and 2–3 μm wide were produced on the sides of fertile hyphae or at the ends of short stalks (Fig. 3). Cylindrical arthroconidia (Fig. 4) 3.5–13 μm long and 2–3.5 μm wide were formed in chains by the fragmentation of hyphae; occasionally arthroconidia were separated by empty cells (alternate arthroconidia). Although both conidial types were usually present, arthroconidia

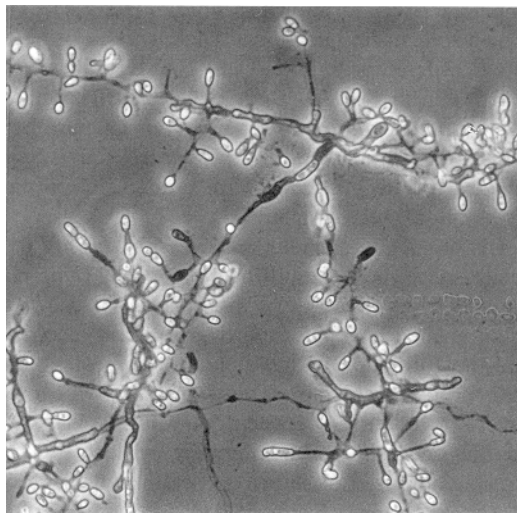


Figure 3. Slide culture preparation of fungus from a brown tree snake, showing pyriform or club-shaped conidia formed on branched hyphae (UAMH 6642). $\times 430$.

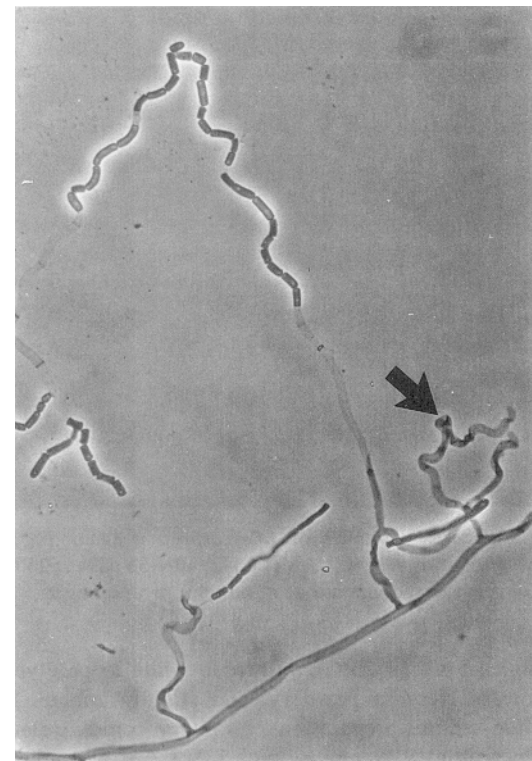


Figure 4. Slide culture preparation of fungus from a brown tree snake, showing lateral branches fragmenting to form arthroconidia and undulate lateral branch (arrow) (UAMH 6642). $\times 430$.

predominated under certain cultural conditions. Another characteristic feature was the presence of undulate (wavy), sparsely septate lateral branches that fragmented to form arthroconidia (Fig. 4). The brown tree snake isolate was most similar in physiological features to an isolate (UAMH 6218) from a captive corn snake. Both isolates differed from other isolates of the *Chrysosporium* anamorph of *N. vriesii* in demonstrating no urease activity and no clearing of milk solids on bromocresol-purple-milk solids-glucose agar.^{12,21}

Histologically, lesions in the skin of all four snakes consisted of multifocal epidermal hyperplasia and hyperkeratosis of the ventral scales, often accompanied by epidermal degeneration, necrosis, and the formation of intraepidermal vesicles filled with protein-rich fluid. These changes were most severe at junctions between the ventral scales and on the underside of overlapping scales (Fig. 5). Crusts composed of serum and cellular debris usually covered these lesions (Figs. 5, 6). Aggregates of bacillary and coccoid bacteria and numerous fungal hyphae were located within serocellular crusts and hyperkeratotic layers of epidermis; fungi

often extended deep into the epidermis (Fig. 7). Fungal hyphae were septate, irregularly branched, and 1.5–3.5 μm wide (Fig. 7). In some lesions, multiple rectangular to oval arthroconidia, 1.5–3.0 μm wide and 2.5–8.0 μm long, were located at the ends of hyphae (Fig. 7); these areas of arthroconidia were correlated with the white powdery areas seen grossly. Infiltrates of low to moderate numbers of lymphocytes, plasma cells, macrophages, and fewer heterophils were present in the dermis and multifocally extended into the overlying epidermis. Occasional fibrin thrombi were located within small blood vessels in the liver of snake 3, liver and kidney of snake 4, and multiple organs in snake 1. Acute renal tubular necrosis was present in snake 1, with precipitation of urate crystals surrounded by heterophils and macrophages in multiple organs, including kidney, liver, spleen, pericardium, and subcutis. No other significant lesions were noted in these snakes.

DISCUSSION

The cutaneous lesions present in these snakes consisted of exudative and proliferative epidermitis with hyperkeratosis, epidermal necrosis, and subacute dermatitis and were associated with superficial fungal and bacterial infections. Several different species of bacteria were isolated from the skins of these snakes, and the bacteria in histologic sections differed in morphology from lesion to lesion. However, the fungi present in the lesions had a uniform morphology, and the same fungus was isolated in pure culture from the skin of each animal cultured, suggesting that this fungus was a consistent and important pathogen.

Grossly, the lesions in these brown tree snakes resembled those reported in several other species of snakes with superficial fungal infections.^{4,7,8,10,11,18} However, in most of the other reported cases of fungal dermatitis in snakes, the clinical course of the disease was more prolonged, and in several instances infections were successfully treated through a combination of improved husbandry and topical application of antifungal creams.^{8,10,24} Povidone-iodine ointment was applied topically to the lesions of three of the snakes, primarily to treat suspected bacterial infections, but did not have any apparent effects on the fungi. Likewise, systemic gentamicin administration did not appear to affect progression of the skin disease in snakes 1 or 2.

The deaths of snakes 2, 3, and 4 were directly attributed to the exudative skin disease. Breakdown of the normal cutaneous barrier caused a combination of body fluid and electrolyte loss through the damaged skin; fungal and/or bacterial toxemia may

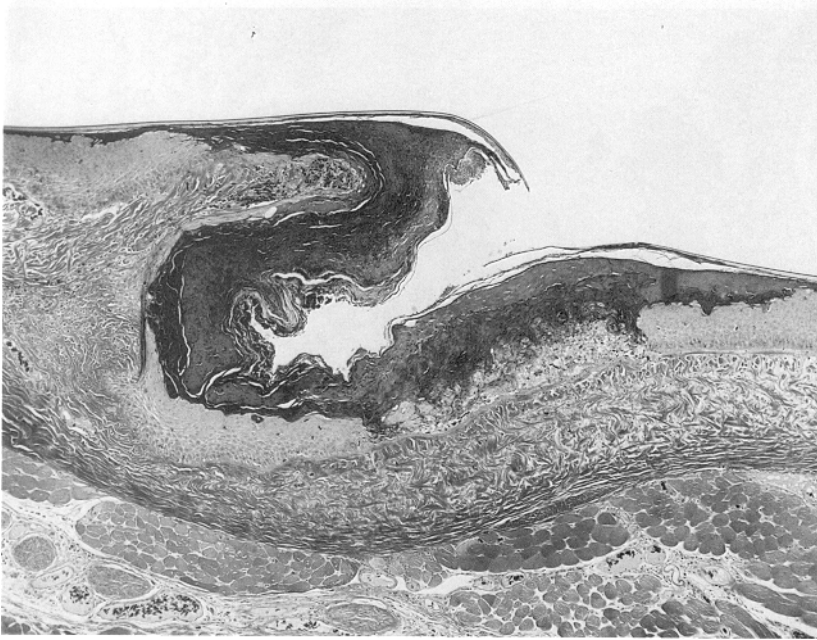

Figure 5. Ventral skin from a brown tree snake with mycotic dermatitis. The epidermis where scales overlap is covered by a thick aggregate of serum, keratin, and degenerate cells. H&E, $\times 48$.

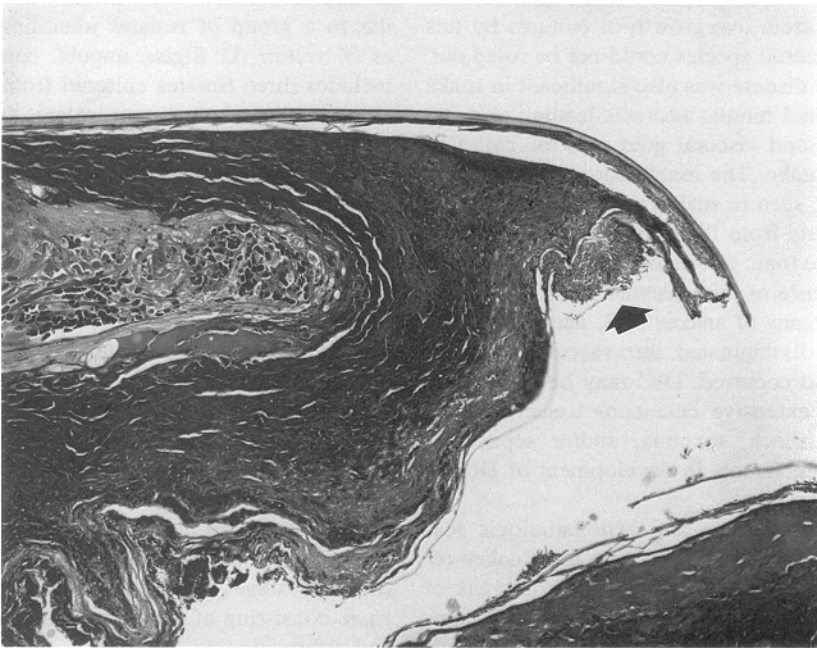


Figure 6. Ventral skin from a brown tree snake with mycotic dermatitis. Higher magnification of Figure 5. A tuft of fungal arthroconidia (arrow) is present superficially on this serocellular crust beneath the scale; these arthroconidia are the granular material noted grossly in Figure 1. H&E, $\times 120$.

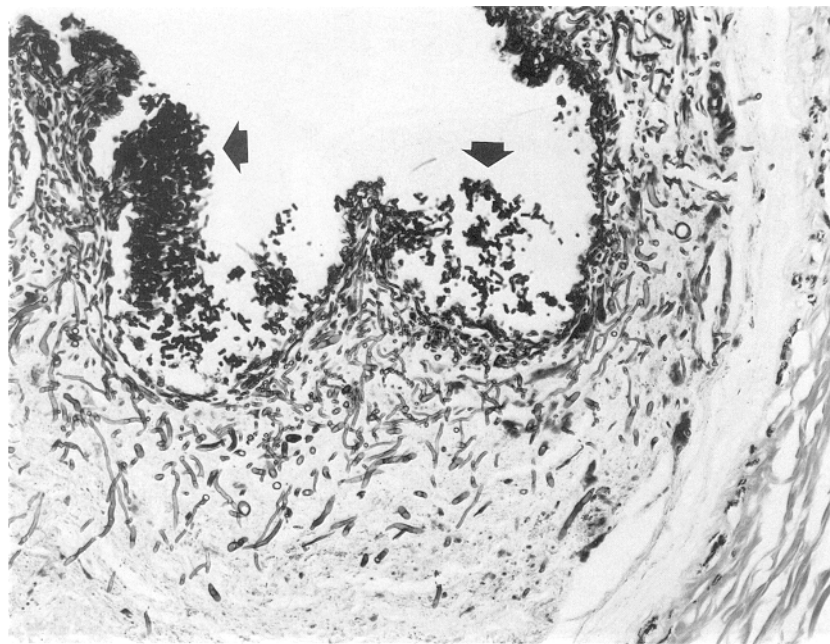


Figure 7. Brown tree snake skin with numerous septate, irregularly branching fungal hyphae extending deep into the epidermis. Aggregates of arthroconidia are present along the surface (arrows). Grocott's methenamine silver, $\times 240$.

have also been factors. Isolation of *Pseudomonas aeruginosa* from the skin and liver of snake 4 suggests that terminal septicemia may have developed in this snake secondary to cutaneous infection, although postmortem overgrowth of cultures by this ubiquitous bacterial species could not be ruled out. The cutaneous disease was also significant in snake 1; however, renal tubular necrosis leading to acute kidney failure and visceral gout was the cause of death in this snake. The renal lesions were consistent with those seen in snakes with gentamicin toxicity;¹⁹ fluid loss from the damaged skin probably exacerbated the toxic effects of the gentamicin therapy. The presence of intravascular fibrin thrombi in the internal organs of snakes 1, 3, and 4 indicates that terminal disseminated intravascular coagulation (DIC) also occurred. DIC may be elicited by many causes; extensive cutaneous tissue damage, hypovolemia, shock, toxemia, and/or septicemia could have been factors in development of DIC in these snakes.

The rapid progression and histopathologic features of the disease in these brown tree snakes resemble those previously reported in an outbreak of *Geotrichum candidum* infection in carpet snakes (*Morelia spilotes variegata*).¹⁸ Similar skin lesions in snakes and lizards have been attributed to *G. candidum*^{20,27} or *Oospora*,¹⁰ a genus name sometimes applied to a fungus forming arthroconidia.²⁵

The fungus isolated from the brown tree snakes was thought initially to be a species of either *Geotrichum* or *Trichosporon* because of its propensity to form arthroconidia but was later shown to be similar to a group of isolates identified provisionally as *N. vriesii* (L. Sigler, unpubl. data). This group includes three isolates cultured from cutaneous lesions in chameleons²¹ and isolates from cutaneous lesions in a royal python (*Python regius*; UAMH 6688), a subcutaneous nodule in a corn snake (UAMH 6218), and a "Madagascar lizard" (lizard species and site of lesion not listed; UAMH 6610). The reptilian isolates were grown on several media at 30°C and under a variety of other conditions; however, no sexual reproduction could be induced, thereby hindering their definitive identification.

Nannizziopsis vriesii is a sexually reproductive species (Ascomycotina, Onygenales) isolated originally from skin and lungs of a lizard (*Ameiva* sp.).^{2,21} One isolate from soil is also known (UAMH 3526). *Nannizziopsis vriesii* forms sexual fruiting bodies (ascocarps containing ascospores) on nutrient-poor medium at 30°C. It also forms an asexual (mitotic) stage considered typical of *Chrysosporium*, consisting of solitary conidia (aleurioconidia) and arthroconidia.

Our findings and those of others²¹ suggest that *N. vriesii* readily infects reptilian tissues and may be involved in deep mycosis.^{2,21} This fungus common-

ly forms arthroconidia in addition to aleurioconidia. Because of this morphologic variability, this fungus could be confused with *G. candidum* or some species of *Chrysosporium* or *Trichophyton*.²¹ Some of the cutaneous or subcutaneous infections of reptiles reported to be due to these fungi^{1,3-5,8-10,13,18,20} may actually be due to *N. vriesii*, but attempts by one of us (LS) to obtain representative isolates for comparison have been unsuccessful.

The source of the fungus in this outbreak is unknown. Immediately following the death of snake 4, all cages in the brown tree snake colony were completely cleaned and disinfected with Betadine and sodium hypochlorite bleach (Clorox, Clorox Co., Oakland, California 94612, USA), and the cage tree branches were discarded and replaced with new ones. The floor, walls, and ceiling of the room in which the snake colony was housed were also scrubbed with Betadine and bleach. Approximately 4 wk later, sterile cotton swabs were used to sample the ventral scales and cloacas of three surviving brown tree snakes, the cages of the dead snakes, and the colony room air vents; these swabs were inoculated onto fungal medium but failed to grow *N. vriesii* (R. Weyant and D. Nichols, unpubl. data).

As with most cutaneous mycoses in snakes, the infections in the brown tree snakes appeared to be opportunistic. The warm, moist conditions under which the snakes were kept were ideal for fungal growth. Daily misting of the snake cages kept the cage floors damp for most of the time each day; prolonged contact of the snakes' ventral scales with wet paper towels likely caused softening of the outer keratinized layers of skin, which then led to decreased resistance to epidermal colonization by bacteria and fungi. Once the fungal infections became established, they spread quickly on the affected snake. Arthroconidium production by the fungi probably aided the rapid transmission of the organisms within a cage and perhaps between cages.

Three weeks prior to the onset of this outbreak, lipids were extracted from the outer layers of skin of these snakes. This process may have altered the composition of the cutaneous layers and further predisposed the snakes to mycotic invasion. Cutaneous lipid extraction into hexane is a well-established procedure that has been performed on several species of reptiles without any associated problems.^{15,17,22,23} Only surface lipids are removed, and there is no evidence that the hexane penetrates internal organs.^{22,23} Since the outbreak described in this report, skin lipids have been extracted numerous times from the surviving brown tree snakes and

there has been no recurrence of the cutaneous mycosis (R. Mason, unpubl. data).

As these cases illustrate, superficial fungal infections can have a significant impact on collections of captive snakes. Under conditions that promote fungal growth and/or increase a snake's susceptibility to fungal colonization, these cutaneous infections can spread quickly and may be fatal. The fungus involved in this outbreak, the *Chrysosporium* anamorph of *Nannizziopsis vriesii*, may be a more significant pathogen of reptiles than has been previously recognized.

Acknowledgments: We thank A. Flis and L. Abbott for technical assistance and the Natural Sciences and Engineering Research Council of Canada for financial support. Photomicrography was performed by R.-A. Ferris at the Armed Forces Institute of Pathology, Washington, D.C.

LITERATURE CITED

1. Abou-Gabal, M., and R. Zenoble. 1980. Subcutaneous mycotic infection of a Burmese python snake. *Mykosen* 23: 627-631.
2. Apinis, A. E. 1970. Concerning *Rollandina*. *Trans. Br. Mycol. Soc.* 55: 499-502.
3. Austwick, P. K. C. 1982. Some mycoses of reptiles. *Congr. Int. Soc. Hum. Anim. Mycol.* 7: 383-384.
4. Austwick, P. K. C., and I. F. Keymer. 1981. Fungi and actinomycetes. *In: Cooper, J. E., and O. F. Jackson (eds.) Diseases of the Reptilia, vol. 1.* Academic Press, New York, New York. Pp. 193-231.
5. Bryant, W. M. 1982. Mycotic dermatitis in a collection of desert lizards. *Proc. Am. Assoc. Zoo Vet.* 1982: 4.
6. Collette, E., and O. H. Curry. 1978. Mycotic keratitis in a reticulated python. *J. Am. Vet. Med. Assoc.* 173: 1117-1118.
7. Dillberger, J., and M. Abou-Gabal. 1979. Mycotic dermatitis in a black ratsnake. *Mykosen* 22: 187-190.
8. Frye, F. L. 1981. *Biomedical and Surgical Aspects of Captive Reptile Husbandry.* Veterinary Medicine Publishing, Edwardsville, Kansas.
9. Hazell, S. L., G. J. Eamens, and R. A. Perry. 1985. Progressive digital necrosis in the eastern blue-tongued skink (*Tiliqua scincoides*). *J. Wildl. Dis.* 21: 186-188.
10. Jacobson, E. R. 1980. Necrotizing mycotic dermatitis in snakes: clinical and pathologic features. *J. Am. Vet. Med. Assoc.* 177: 838-841.
11. Jacobson, E. R. 1989. Mycotic diseases of amphibians and reptiles: a review. *Proc. Int. Colloq. Pathol. Rept. Amphib.* 3: 41-42.
12. Kane, J., R. C. Summerbell, L. Sigler, S. Krajden, and G. Land. 1997. *Laboratory Handbook of Dermatophytes. A Clinical Guide and Laboratory Manual of Dermatophytes and Other Filamentous Fungi from Skin, Hair, and Nails.* Star, Belmont, California.
13. Keymer, I. F. 1976. Report of the pathologist, 1973 and 1974. *J. Zool. Lond.* 178: 470-471.
14. Marcus, L. C. 1981. *Veterinary Biology and Med-*

icine of Captive Amphibians and Reptiles. Lea & Febiger, Philadelphia, Pennsylvania.

15. Mason, R. T., H. M. Fales, T. H. Jones, L. K. Pannell, J. W. Chinn, and D. Crews. 1989. Sex pheromones in snakes. *Science* 245: 290–293.

16. Mason, R. T., R. F. Hoyt, L. K. Pannell, E. F. Wellner, and B. Demeter. 1991. Cage design and configuration for arboreal reptiles. *Lab. Anim. Sci.* 41: 84–86.

17. Mason, R. T., T. H. Jones, H. M. Fales, L. K. Pannell, and D. Crews. 1990. Characterization, synthesis, and behavioral response to the sex attractiveness pheromones of the red-sided garter snake (*Thamnophis sirtalis parietalis*). *J. Chem. Ecol.* 16: 2353–2369.

18. McKenzie, R. A., and P. E. Green. 1976. Mycotic dermatitis in captive carpet snakes (*Morelia spilotes variegata*). *J. Wildl. Dis.* 12: 405–408.

19. Montali, R. J., M. Bush, and J. M. Smeller. 1979. The pathology of nephrotoxicity of gentamicin in snakes: a model for reptilian gout. *Vet. Pathol.* 16: 108–115.

20. Page, L. A. 1966. Diseases and infections of snakes: a review. *Bull. Wildl. Dis. Assoc.* 2: 111–125.

21. Pare, J. A., L. Sigler, D. B. Hunter, R. C. Sumnerbell, D. A. Smith, and K. L. Machin. 1997. Cutaneous mycoses in chameleons caused by the *Chrysosporium* anamorph of *Nannizziopsis vriesii* (Apinis) Currah. *J. Zoo Wildl. Med.* 28: 443–453.

22. Roberts, J. B., and H. B. Lillywhite. 1980. Lipid barrier to water exchange in reptile epidermis. *Science* 207: 1077–1079.

23. Roberts, J. B., and H. B. Lillywhite. 1983. Lipids and the permeability of the epidermis from snakes. *J. Exp. Zool.* 228: 1–9.

24. Schildger, B. J., H. Frank, T. Gobel, and R. Weib. 1989. Mycotic infections of the integument and inner organs in reptiles. *Proc. Int. Colloq. Pathol. Rept. Amphib.* 3: 46.

25. Sigler, L., and J. W. Carmichael. 1976. Taxonomy of *Malbranchea* and some other *Hyphomycetes* with arthroconidia. *Mycotaxon* 4: 349–488.

26. Werner, R., M. A. Balady, and G. J. Kolaja. 1978. Phycomycotic dermatitis in an eastern indigo snake. *Vet. Med. Small Anim. Clin.* 73: 362–363.

27. Wissman, M. A., and B. Parsons. 1993. Dermato-phytosis of green iguanas (*Iguana iguana*). *J. Small Exotic Anim. Med.* 203: 137–140.

28. Zwart, P., M. A. J. Verwer, G. A. de Vries, E. J. Hermanides-Nijhof, and H. W. de Vries. 1973. Fungal infection of the eyes of the snake *Epicrates chenchria maurus*: enucleation under halothane narcosis. *J. Small Anim. Pract.* 14: 773–779.

Received for publication 5 September 1997